

CERVICAL CANCER ^{1,2}

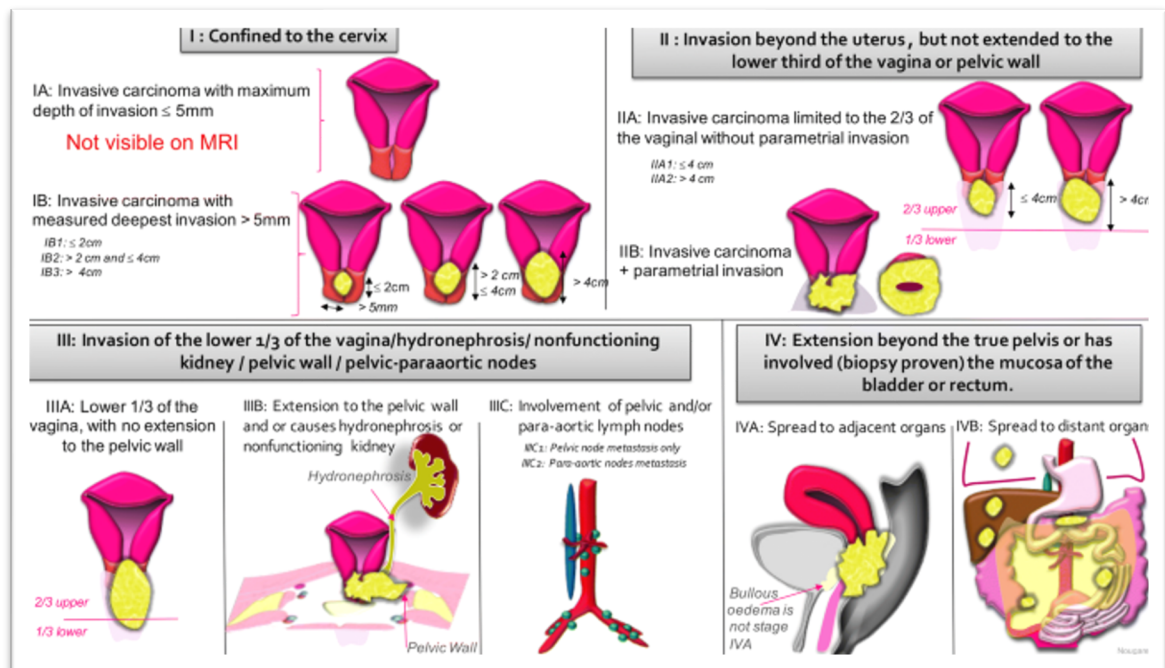
General Overview

- 4th most common cancer in women worldwide
 - Highest incidence between 35-44 years
 - Highest incidence in low-income countries due to a lack of screening
- Risk factors: HPV infection (immune suppression, history of sexual transmitted disease, multiple partners), smoking, low socio-economic status
- Pathophysiology: persistent HPV infection (70% = HPV type 16 and 18)
- Findings/symptoms: abnormal cells on pap smear, bleeding, vaginal discharge, pelvic pain
- Two main histological subtypes: squamous cell carcinoma and adenocarcinoma
- Prevention:
 - Primary: vaccination (Gardasil 9[®] - nonavalent vaccine), most effective in HPV-naïve patients, number needed to treat for vaccination to prevent new HPV-infections/precursor lesions after HPV-exposure: 1/42, no reimbursement after age of 19 years in Belgium (cost: €150 per vaccine, 3 vaccines needed)
 - Secondary: screening (pap smear and HPV detection) and treatment (LLETZ) of precursor lesions (CIN 2-3)

Staging (2018 FIGO classification) and Prognosis

- Physical examination (if necessary under anesthesia) with pap smear and biopsy
- Disease extent: transvaginal ultrasound, MRI of the pelvis, (PET-)CT
- Full lab including SCC tumor marker

Figure 1: 2018 FIGO classification



FIGO 2018 classification

Stage 1: The carcinoma is strictly confined to the cervix (extension to the uterine corpus should be disregarded)

IA: Invasive carcinoma that can be diagnosed only by microscopy, with maximum depth of invasion ≤ 5 mm

IA1: Measured stromal invasion ≤ 3 mm in depth

IA2: Measured stromal invasion >3 and ≤ 5 mm in depth

IB: Invasive carcinoma with measured deepest invasion >5 mm (greater than Stage IA); lesion limited to the cervix uteri with size measured by maximum tumor diameter

IB1: Invasive carcinoma >5 mm depth of stromal invasion and ≤ 2 cm in greatest dimension

IB2: Invasive carcinoma >2 and ≤ 4 cm in greatest dimension

IB3: Invasive carcinoma >4 cm in greatest dimension

Stage 2: The carcinoma invades beyond the uterus, but has not extended onto the lower third of the vagina or to the pelvic wall

IIA: Involvement limited to the upper two-thirds of the vagina without parametrial involvement

IIA1: Invasive carcinoma ≤ 4 cm in greatest dimension

IIA2: Invasive carcinoma >4 cm in greatest dimension

IIB: With parametrial involvement but not up to the pelvic wall

Stage 3: The carcinoma involves the lower third of the vagina and/or extends to the pelvic wall and/or causes hydronephrosis or nonfunctioning kidney and/or involves pelvic and/or para-aortic lymph nodes

IIIA: The carcinoma involves the lower third of the vagina, with no extension to the pelvic wall

IIIB: Extension to the pelvic wall and/or hydronephrosis or nonfunctioning kidney (unless known to be due to another cause)

IIIC: Involvement of pelvic and/or para-aortic lymph nodes (including micrometastases), irrespective of tumor size and extent (with r and p notations)

IIIC1: Pelvic lymph node metastasis only

IIIC2: Para-aortic lymph node metastasis

Stage 4: The carcinoma has extended beyond the true pelvis or has involved (biopsy proven) the mucosa of the bladder or rectum. A bullous edema, as such, does not permit a case to be allotted to Stage IV

IVA: Spread of the growth to adjacent pelvic organs

IVB: Spread to distant organs

- Prognosis depends on stage of the disease
 - 5-year overall survival stage IIB-IVA: 73-20%
 - Risk of recurrence: 45% in first 2 years
 - Median survival after recurrence: 12 months

Figure 2: 5-year overall survival

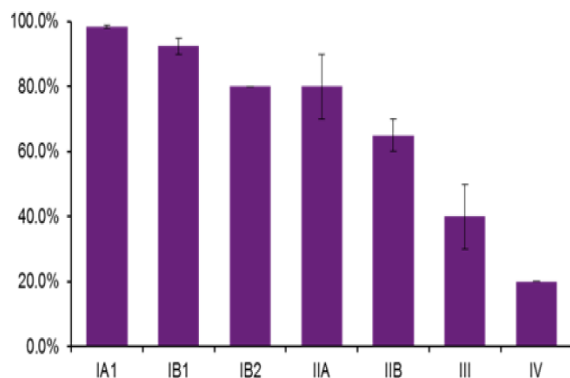
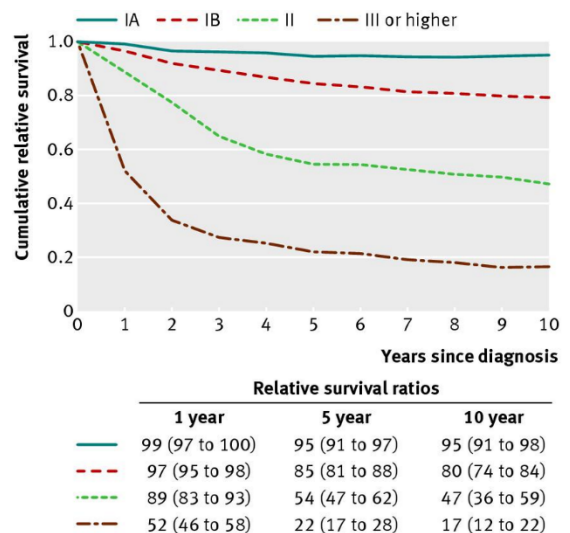


Figure 3: relative survival ratios of cervical cancer for women of all ages, by FIGO stage



Treatment

SURGERY

- Indication: tumors ≤ 4 cm without lymph node (LN) involvement
- Technique:
 - FIGO stage IA: conization/LLETZ +/- sentinel node procedure (if LVSI +)
 - FIGO stage IA2-IB1 (≤ 2 cm): simple hysterectomy with sentinel node procedure ^{3,4}
 - FIGO stage IB2-IIA1: radical hysterectomy + sentinel node procedure +/- pelvic lymphadenectomy; via open surgery (better OS compared to minimally invasive) ⁵
 - Consider fertility sparing surgery in young patients after discussion of potential risks: trachelectomy + sentinel node procedure +/- cerclage
- Sentinel node procedure: two step procedure ⁶
 - Step 1: sentinel node excision + ultra-staging
 - Step 2:
 - if LN negative: completion of (radical) hysterectomy
 - if LN positive: chemoradiation
- Adjuvant treatment:
 - High risk patients (LN +, involvement of surgical margins, parametrial involvement): adjuvant chemoradiation (with cisplatin) +/- brachytherapy
 - Intermediate risk patients (cfr. Sedlis criteria ⁷): adjuvant radiation therapy

Sedlis criteria		
Lymphovascular space invasion	Stromal invasion	Tumor size by clinical palpation
+	Deep 1/3	Any
+	Middle 1/3	≥ 2 cm
+	Superficial 1/3	≥ 5 cm
-	Middle or deep 1/3	≥ 4 cm

CHEMORADIATION THERAPY

- Stage IB3-IVA and inoperable stage IB1-IIA1
 - External beam radiation therapy (EBRT, 25x1.8Gy + 25x 0.4/0.5Gy on lymph nodes that appear pathological on imaging) + concomitant cisplatin (40mg/m² q1w during radiation therapy) + brachytherapy (2x14Gy), aim for total treatment time < 7 weeks
 - For patients with FIGO 2014 stage III-IVA disease: addition of 5 cycles pembrolizumab 200mg q3w starting together with chemoradiotherapy, followed by 15 cycles pembrolizumab 400mg q6w improves PFS and OS (study population: FIGO 2014 IB2-IIB LN+, III-IVA regardless of LN) ⁸
 - For patients with FIGO 2018 stage IB3, II, IIIC (if no overlapping criteria of IIIA-IIIB) disease: addition of induction chemotherapy (carboplatin AUC2 + paclitaxel 80mg/m² q1w x 6 weeks) improves PFS and OS ⁹ (study population: FIGO 2008 IB1 LN+, IB2, IIA, IIB, IIIB, IVA)
 - Consider para-aortal lymph node dissection if negative on imaging to determine extent of the radiation field
- Neo-adjuvant chemotherapy followed by radical surgery:
 - No difference in OS but better DFS in chemoradiation group: chemoradiation therapy is preferred ^{10,11}

LOCAL TREATMENT OF RECURRENT DISEASE

- Surgical exenteration (anterior/posterior/both) when treated with radiation therapy before, associated with high risk of major complications (21%) and poor prognosis (5y OS 38%)
- Definitive chemoradiation if sidewall pelvic recurrence after primary surgery in radiotherapy naïve patients

SYSTEMIC THERAPY

- Indication: stage IVB or systemic recurrent disease
- First line: cisplatin 50mg/m² q3w + paclitaxel 135mg/m² q3w ¹² or carboplatin AUC5 q3w + paclitaxel 175mg/m² q3w ¹³
 - preference for cisplatin if not received prior
 - + [bevacizumab](#) 15mg/kg q3w if no infiltration in rectum/bladder ¹⁴
 - + [pembrolizumab](#) 200mg q3w if PD-L1 CPS ≥ 1 ¹⁵
- Second line:
 - [cemiplimab](#): if not received prior IO, regardless of PD-L1 status ¹⁶
 - chemotherapy: response rates 0-29%, PFS 2-5 months, OS 5-12 months with different agents, no agent is specifically recommended

Follow-up

- Pelvic MRI 8-12w after chemoradiation therapy
- Physical examination every 3-4 months in the first 2 years, then every 6 months in year 3-5
- No evidence to support follow-up with pap smear and HPV detection, especially not in patients treated with chemoradiation therapy
- To consider: CT thorax every year, other imaging studies only on indication

What's new

- BEATcc trial: addition of atezolizumab to cis/carboplatin + paclitaxel + bevacizumab in 1st line improves PFS and OS regardless of PD-L1 status, no reimbursement in Belgium yet ¹⁷
- Innova301 trial: tisotumab vedotin vs TPC improvement of PFS, OS and ORR in second/third line ¹⁸, ongoing trials are testing TV + carboplatin in 1st line and TV + pembrolizumab in 2nd and 3rd line

References

- 1 Cibula, D. *et al. Virchows Arch* 482, 935–966 (2023)
- 2 Marth, C. *et al. Ann Oncol* 28, iv72–iv83 (2017)
- 3 Kocian, R. *et al. Gynecol Oncol* 188, 83–89 (2024)
- 4 Plante, M. *et al. N Engl J Med* 390, 819–829 (2024)
- 5 Ramirez, P. T. *et al. N Engl J Med* 379, 1895–1904 (2018)
- 6 Cibula, D. *et al. Eur J Cancer* 143, 88–100 (2021)
- 7 Sedlis, A. *et al. Gynecol Oncol* 73, 177–83 (1999)
- 8 Lorusso, D. *et al. Lancet* 403, 1341–1350 (2024)
- 9 McCormack, M. *et al. Annals of Oncology* 34, S1276 (2023)
- 10 Kenter, G. G. *et al. J Clin Oncol* 41, 5035–5043 (2023)
- 11 Gupta, S. *et al. J Clin Oncol* 36, 1548–1555 (2018)
- 12 Monk, B. J. *et al. J Clin Oncol* 27, 4649–55 (2009)

- 13** Kitagawa, R. *et al. J Clin Oncol* 33, 2129–35 (2015)
- 14** Tewari, K. S. *et al. Lancet* 390, 1654–1663 (2017)
- 15** Monk, B. J. *et al. J Clin Oncol* 41, 5505–5511 (2023)
- 16** Tewari, K. S. *et al. N Engl J Med* 386, 544–555 (2022)
- 17** Oaknin, A. *et al. Lancet* 403, 31–43 (2024)
- 18** Vergote, I. *et al. New England Journal of Medicine* 391, 44–55 (2024)

FIGO 2008 classification

Stage 1: The carcinoma is strictly confined to the cervix (extension to the uterine corpus would be disregarded)

IA: Invasive carcinoma which can be diagnosed only by microscopy, with deepest invasion ≤ 5 mm and largest extension ≥ 7 mm

IA1: Measured stromal invasion of ≤ 3.0 mm in depth and extension of ≤ 7.0 mm

IA2: Measured stromal invasion of >3.0 mm and not >5.0 mm with an extension of not >7.0 mm

IB: Clinically visible lesions limited to the cervix uteri or pre-clinical cancers greater than stage IA

IB1: Clinically visible lesion ≤ 4.0 cm in greatest dimension

IB2: Clinically visible lesion >4.0 cm in greatest dimension

Stage 2: Cervical carcinoma invades beyond the uterus, but not to the pelvic wall or to the lower third of the vagina

IIA: Without parametrial invasion

IIA1: Clinically visible lesion ≤ 4.0 cm in greatest dimension

IIA2: Clinically visible lesion >4 cm in greatest dimension

IIB: With obvious parametrial invasion

Stage 3: The tumor extends to the pelvic wall and/or involves lower third of the vagina and/or causes hydronephrosis or non-functioning kidney

IIIA: Tumor involves lower third of the vagina, with no extension to the pelvic wall

IIIB: Extension to the pelvic wall and/or hydronephrosis or non-functioning kidney

Stage 4: The carcinoma has extended beyond the true pelvis or has involved (biopsy proven) the mucosa of the bladder or rectum. A bullous edema, as such, does not permit a case to be allotted to Stage IV

IVA: Spread of the growth to adjacent organs

IVB: Spread to distant organs

FIGO 2014 classification

Stage 1: The carcinoma is strictly confined to the cervix (extension to the uterine corpus should be disregarded)

IA: Invasive cancer identified only microscopically. (All gross lesions even with superficial invasion are Stage IB cancers.) Invasion is limited to measured stromal invasion with a maximum depth of 5 mm and no wider than 7 mm

IA1: Measured invasion of stroma ≤ 3 mm in depth and ≤ 7 mm width

IA2: Measured invasion of stroma > 3 mm and < 5 mm in depth and ≤ 7 mm width

IB: Clinical lesions confined to the cervix, or preclinical lesions greater than stage IA

IB1: Clinical lesions no greater than 4 cm in size.

IB2: Clinical lesions > 4 cm in size

Stage 2: The carcinoma extends beyond the uterus, but has not extended onto the pelvic wall or to the lower third of vagina

IIA: Involvement of up to the upper 2/3 of the vagina. No obvious parametrial involvement

IIA1: Clinically visible lesion ≤ 4 cm

IIA2: Clinically visible lesion > 4 cm

IIB: Obvious parametrial involvement but not onto the pelvic sidewall

Stage 3: The carcinoma has extended onto the pelvic sidewall. On rectal examination, there is no cancer free space between the tumor and pelvic sidewall. The tumor involves the lower third of the vagina. All cases of hydronephrosis or non-functioning kidney should be included unless they are known to be due to other causes

IIIA: Involvement of the lower vagina but no extension onto pelvic sidewall

IIIB: Extension onto the pelvic sidewall, or hydronephrosis/non-functioning kidney

Stage 4: The carcinoma has extended beyond the true pelvis or has clinically involved the mucosa of the bladder and/or rectum

IVA: Spread to adjacent pelvic organs

IVB: Spread to distant organs